

M.O.R.E. Journal

S U P P L E M E N T

AMIS PUBLICATION REVIEW

APRIL 2016

The official Journal of the

 **.O.R.E.**
I N S T I T U T E

MEDACTA ORTHOPAEDIC
RESEARCH AND **EDUCATION**

A  IS

ANTERIOR MINIMALLY INVASIVE SURGERY
IN HIP REPLACEMENT

AMIS

ANTERIOR MINIMALLY INVASIVE SURGERY
IN HIP REPLACEMENT

MORE THAN
200,000
AMIS

Leader in **Anterior
Approach** Education



© 2016 Medacta International SA. All rights reserved.

MEDACTA.COM

 **edacta**
International 

Introduction

The anterior approach to the hip is the only one that makes use of a true intermuscular and internervous interval, which follows the path between the sartorius/rectus femoris and the tensor fascia lata muscle (TFL) to access the hip joint, resulting in a less invasive technique due to the fact that it does not adversely affect any of the major muscle groups around the hip joint^[1,2,3].

Convinced of the value of this approach for improved patient wellbeing, the AMIS International Educational Board (constituted by an international group of expert surgeons) with the support of Medacta have developed a minimally invasive surgery (MIS) anterior approach procedure named AMIS (Anterior Minimally Invasive Surgery). The main goal was (and still is) to optimize and standardize the anterior approach to make it more straightforward and enhance its reproducibility, having developed specific instruments and implants in order to achieve this.

Almost from its inception it was clear that the AMIS approach had the potential to provide relevant clinical advantages, and so effective widespread teaching of the technique, became the goal. The M.O.R.E. (Medacta Orthopaedic Research and Development) Institute was created, and together with the AMIS International Education Board became responsible for the development and the continuous improvement of the AMIS Education Program. Medacta constantly invests in this education program, to provide ongoing surgeon training and proctorship, and reduction to the minimal possible initial learning curve, with the result that surgeons, hospitals, and more importantly patients worldwide can hopefully benefit from the AMIS advantages.

The main goal of this document is to review the published studies regarding the anterior approach (including the studies realized on the AMIS), to demonstrate the important advantages of adopting it for THA. This document is divided into:

- An overview of the anterior approach history with the most important landmarks;
- A summary of the AMIS history together with a description of the main advantages versus other anterior approaches;
- A review of the anterior approach studies published in literature;
- A discussion of what is reported in this document.

Acknowledgements

Thanks to

DR. FRÉDÉRIC LAUDE
(CMC Paris V, Paris, France)

DR. SERGIO CANDIOTTO
(Ospedale Sant'Antonio, Padova, Italy)

PROF. CESARE FALDINI
(Istituto Ortopedico Rizzoli, Bagheria, Italy)

for allowing us to use the images contained within this document.

Index

HISTORY OF THE ANTERIOR APPROACH	1
THE AMIS APPROACH	2
■ History of the AMIS approach	2
■ The AMIS approach	4
PUBLICATION REVIEW	7
■ Minimally invasive anterior approach/AMIS publication review	7
■ Anterior approach vs other approaches	11
■ Minimally invasive anterior approach - controversial results	15
DISCUSSION	17

History of the anterior approach

The first written description of the anterior approach is attributed to a German surgeon named Carl Hueter (1838-1882), in his work “Grundriss der Chirurgie” (The Compendium of Surgery) published in 1881. However, the credit for spreading it in the English-speaking countries is given to Marius N. Smith-Petersen (1886-1953), who described the technique in 1917 in his study “A new supra-articular subperiosteal approach to the hip joint”, based on Hueter’s original description. This explains why the anterior approach is commonly referred to as the “Smith-Petersen approach”^[1,4].

Initially, the anterior approach was mainly used to treat developmental hip dysplasia, fractures of the hip and femoro-acetabular impingement, being used and re-described by many surgeons^[1]. Its first use in Total Hip Arthroplasty (THA) was reported in 1947, when Robert Judet performed it with the patient supine and assisted by the Judet table (designed by Henry Judet, his father, in 1940)^[2]. From all the reasons that led Robert Judet to choose this approach for hip arthroplasty, the most important were: the anterior approach is a more direct way to the hip joint because it is an anterior articulation; it follows an intermuscular (between sartorius/rectus femoris and TFL) and internervous (between the zones of innervation of the gluteal and femoral nerves) path; it allows the hip exposure without detaching muscles from bone^[5].

Nevertheless, Charnley’s success using the transtrochanteric approach combined with the reported concerns about a difficult introduction of the femoral components (which at this time were very bulky) through the anterior approach, led to a rare use of the anterior approach in hip arthroplasty^[1], with punctual exceptions like the Judet brothers (which advocated the use of the anterior approach for hip arthroplasty with the aid of an orthopaedic traction table, describing this


procedure in 1985 in their publication “Voie d’abord antérieure dans l’arthroplastie totale de la hanche”^[1,6]). In the beginning of the XXI century the concept of MIS for hip arthroplasty appeared. The main focus was then on the length of the skin incision, typically less than 10 or 12 cm^[7]. This trend led to the development of several so-called mini invasive solutions for hip arthroplasty, like the 2-incision, mini-posterior, mini-lateral, mini-antrolateral, etc. However, the studies published on these approaches were controversial and were not able to provide definite proof of their added value^[8,9,10,11].

At this point, the anterior approach (in particular the MIS variants) gained popularity because it was seen as the solution that could avoid the reported problems

encountered with other hip approaches, among them the potential high rate of complications and technically demanding procedure^[11,12] for the 2-incision technique; hip dislocation with the (mini) posterior approach^[8,13]; potential delay in functional recovery and residual trochanteric pain and limping for the (mini) lateral approach^[14]; potential risk of damaging the superior gluteal nerve^[9,15], tensor fascia lata denervation^[16,17] and gluteus minimus fatty atrophy^[18] for the (mini) anterolateral approach. The acceptance of

the anterior approach started to increase, also because of new reports being published, like those performed by Siguier and colleagues^[19] and by Matta and colleagues^[5,20].

Nowadays, the anterior approach is widely used for the implantation of hip prostheses and is especially used as minimally invasive surgery, being recognized as the least invasive approach for hip arthroplasty^[1,2,19]. It is estimated that 10% of the hip replacements worldwide are done through the anterior approach^[21], a growth in acceptance to which the AMIS has highly contributed.



The AMIS approach

The AMIS (Anterior Minimally Invasive Surgery) approach describes a minimally invasive anterior approach for hip arthroplasty, developed by the AMIS International Education Board, which represents a group of international AMIS pioneers responsible for the development and the continuous improvement of the technique, with the support of Medacta. This Chapter will resume the tale of the AMIS and will provide a summarized description of the technique in order to highlight its main benefits when compared with other anterior approach techniques.

HISTORY OF THE AMIS APPROACH

The history of the AMIS approach is connected to the recent history of the anterior approach. When the MIS trend arrived some surgeons were already performing hip arthroplasty through the minimally invasive anterior approach^[19,20]. These studies defended the use of an extension table to perform it, but the availability of these devices at this time was very limited and those available demanded a large investment by the hospitals wishing to acquire them.

Dr. Frédéric Laude, a French surgeon experienced in the minimally invasive anterior approach (since 1995), had developed an extension table, but wished to improve its characteristics. In 2004, Dr. Laude presented his concept for the anterior approach to Medacta. His core idea was to focus on patient wellbeing, performing the most-tissue-preserving surgical technique for Total Hip Replacement: the Minimally Invasive Anterior Approach. Dr. Laude asked Medacta to optimize and enhance the reproducibility of the anterior approach, developing new dedicated implants and instruments. This idea was perfectly in line with Medacta's vision of creating a better patient experience for people needing joint replacement. Dr. Laude and Medacta decided to create a new word for this synergy: AMIS, which means Anterior Minimally Invasive Surgery, but also "friends" in French.

The first step was to develop a Mobile Leg Positioner to correctly perform the AMIS approach. In fact, stable and reproducible leg positioning is essential to enable an easier exposure and a simple and reproducible surgical procedure to restore patient anatomy and function. As Medacta develops its products through a holistic approach, AMIS is not only a surgical technique, but also a complete set of services for the surgeon who wants to perform the anterior approach, including dedicated implants and instruments. The

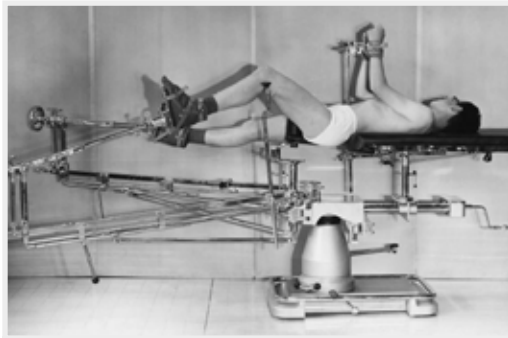
AMIS dedicated instruments address bone preparation and prosthesis implantation, but are also a valid tool to optimize the approach:

- The acetabular reamer and impactor and the femoral handle were adapted in order to avoid the surrounding soft tissues, which could make it difficult to correctly ream and implant the final shell;
- The stability provided by the AMIS Mobile Leg Positioner, meant that self-retaining retractors could be applied during AMIS. So Medacta developed some solutions that could be used efficiently through the AMIS procedure without damaging any major muscles. These devices were an important step in the development of AMIS: not only was the procedure simplified but also the extensive use of Hohmann retractors was avoided, potentially reducing the risk of nerve or muscle damage^[5]. Preferred retractors were the modified Beckmann and the AMIS Charnley retractors.

With regard to the implants and the knowledge that the bulkier the femoral stems the more difficult is to implant them, Medacta developed femoral stem systems that could be easily introduced through the AMIS.

- Quadra system – the first Medacta stem that could be easily used with the AMIS, in the market since 2003.
- MiniMAX – the anatomic solution also easily introduced by the AMIS approach, in the market since 2007.
- AMISstem – the first femoral stem specifically designed for the AMIS approach, introduced in 2009.

From its inception it is clear that the AMIS approach has the potential to provide relevant clinical advantages to the patient, but also that Minimally Invasive Surgery is a difficult adaptation and a steep learning curve is often encountered during the initial cases. This learning curve has discouraged many surgeons and caused them to abandon MIS/LIS for other techniques. Medacta's mission is to reduce learning curve difficulties by providing unconditional support, through an ongoing process of medical education for surgeons who seek to adopt AMIS. For this reason, in 2005 six international AMIS pioneers – Dr. Frédéric Laude (Clinique Paris V – Paris, France), Prof. Claudio Dora (Uniklinik Balgrist – Zurich, Switzerland), Prof. André Gächter (BeritKlinik – St. Gallen, Switzerland), Dr. Fabian Kalberer (Kantospital Winterthur – Winterthur, Switzerland), Dr. Pascal Moreau (Polyclinique de Montier La Celle – Troyes, France) and Dr. Pascal Vié (Clinique du



1947 - Original Judet's Leg Positioner



1996 - Dr. Laude's First Leg Positioner



2004 - AMIS Mobile Leg Positioner



2011 - AMIS Mobile Leg Positioner 2.0

Cèdre – Bois Guillaume, France) – created the AMIS International Education Board, responsible for the development and the continuous improvement of the AMIS Education Program. Medacta constantly invest in this education program, to provide ongoing surgeon training and proctorship.

In the following years, the concept of AMIS evolved to provide a complete system of tools and services to support the surgeons willing to begin the process of adopting the anterior approach. Nowadays, the M.O.R.E. AMIS Education Program is a comprehensive set of courses for continuous medical education. It has been developed to help the surgeon mastering the AMIS approach through different levels of learning which are:

- The Instructional Level, designed to allow the surgeon to avoid predictable complications, minimize the learning curve, and also provide some important “pearls” to ease the transition to AMIS.
- The Advanced Level, introduced to improve the AMIS technique and widen patient selection. It focuses on detailed scientific topics to stimulate expert-to-expert open discussion, increasing confidence in AMIS and widening patient selection to almost all primary cases.
- The Master Level, recently created to allow surgeons to master the AMIS technique, focusing on difficult cases and revisions. The Revision AMIS Learning Center offers the opportunity to learn and try different strategies for complex revision arthroplasties in cadaver workshops.

After 10 years of experience, the M.O.R.E. AMIS Education Program allowed a successful diffusion of the AMIS approach all over the world and made Medacta the “Best in Class” on anterior approach education. This statement is supported by the overall AMIS numbers:

- The AMIS Education Board now features more than 100 expert surgeons worldwide. Each of them represents a Reference Center that welcomes visiting surgeons for an introduction to the technique, and possible assistance for their first surgeries.
- As a result of the AMIS Education Program, more than 3'200 Reference Center visits have been arranged and more than 2'500 participants have attended Learning Centers, 80% of whom have continued to use the AMIS approach.
- More than 150 Learning Centers have been conducted, and Medacta continues to organize approximately 40 Learning Centers worldwide each year.
- Globally, there are more than 1'000 AMIS users and more than 200'000 hip replacements have been performed through the AMIS approach.

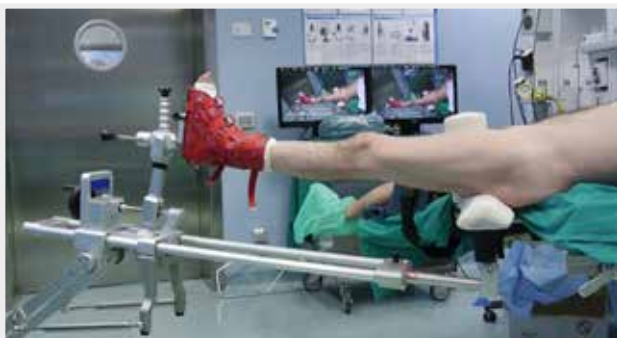AMIS has already had a major impact on the global orthopaedic market. Medacta's promise for the future is a strong commitment to keep evolving always in the direction of providing the best support, the best solutions and continued efforts to add value to your practice and hospitals.

THE AMIS APPROACH

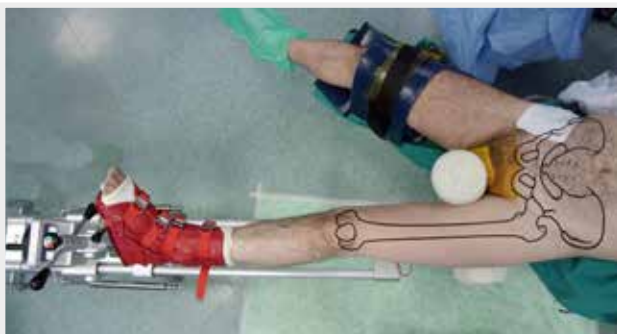The AMIS approach is well described in the literature^[22,23,24]. There are some specific steps which are characteristic to this approach and differentiate it from other MIS anterior approach techniques available. Below, these steps are summarized:

Patient positioning

The first step specific to the AMIS approach regards the patient positioning. The AMIS is performed with the assistance of the AMIS Mobile Leg Positioner, which is able to be attached to every orthopaedic table. With the patient lying supine, his (her) leg is set up on the AMIS Mobile Leg Positioner.



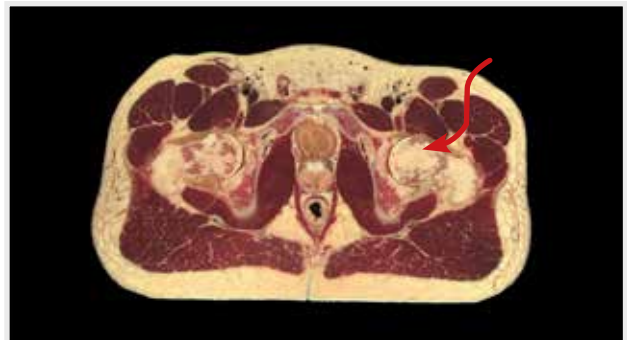By courtesy of Prof. Faldini



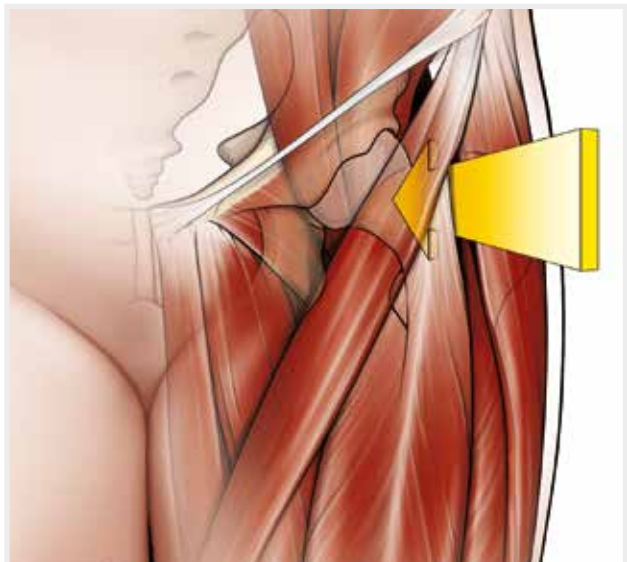
By courtesy of Prof. Faldini

Skin incision

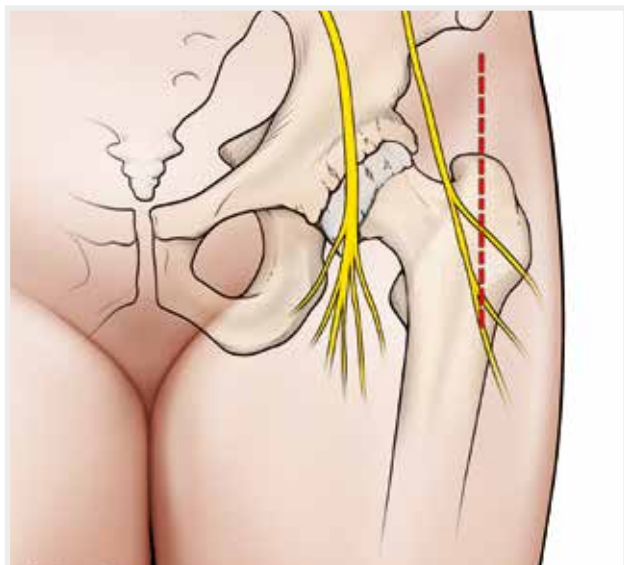
The AMIS is more lateral than the classic Hueter approach in order to avoid injuring the femoral cutaneous nerve and its branches. The skin incision is extended straight to the superficial aponeurosis of the TFL.



By courtesy of Prof. Faldini



By courtesy of Dr. S. Candiotti (© M. Crespi)

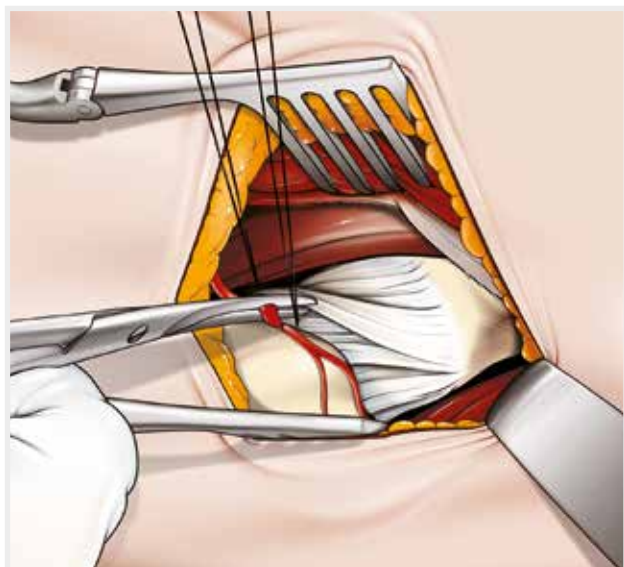


By courtesy of Dr. S. Candiottio (© M. Crespi)

Surgical exposure

During the surgical exposure there are 2 characteristic steps to the AMIS approach.

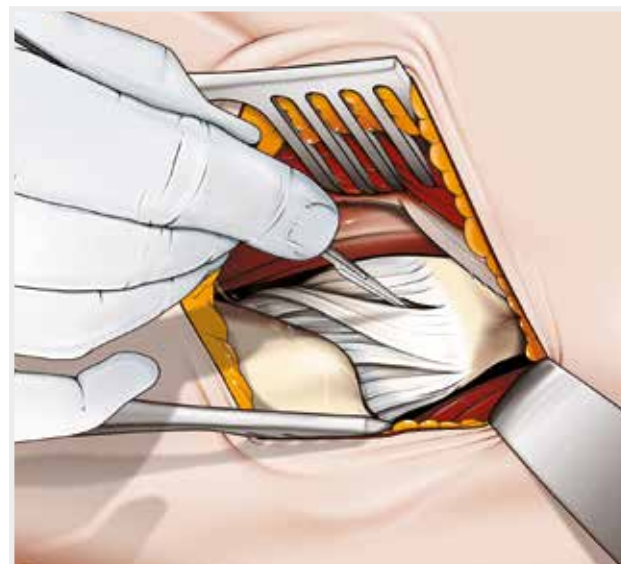
- The use of a modified Beckmann, a self-retaining retractor which eases the surgical exposure and avoids excessive use of other retractors potentially reducing the risk of nerve or muscle damage^[5].
- The ligation of the circumflex arterio-venous bundle after having passed between the TFL and the rectus femoris, to avoid excessive bleeding.



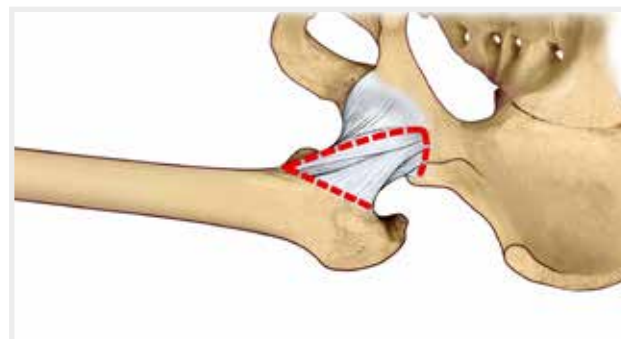By courtesy of Dr. S. Candiottio (© M. Crespi)

Articular approach

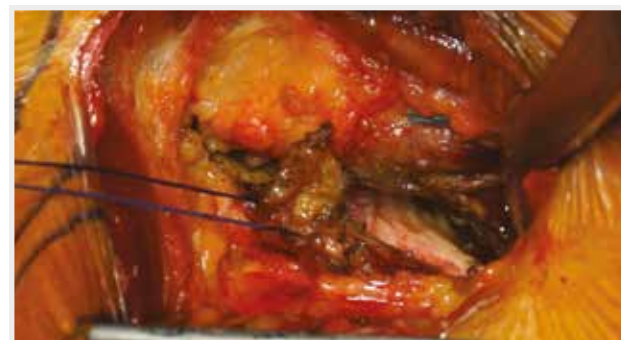The access to the hip capsule does not involve a capsulectomy. The capsule is opened precisely and a flap is detached for supporting the modified Charnley retractor.



By courtesy of Dr. S. Candiottio (© M. Crespi)



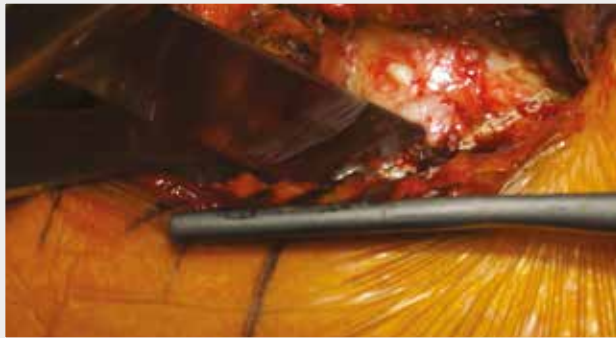By courtesy of Prof. Faldini



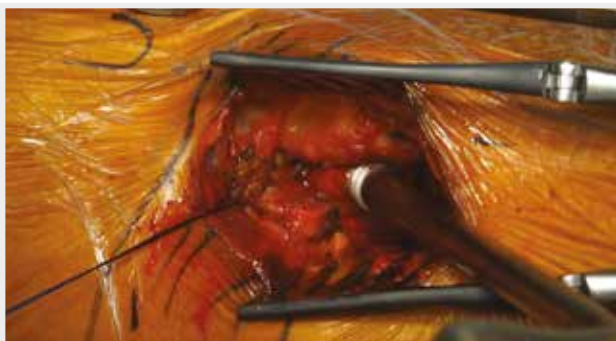By courtesy of Dr. Laude

Femoral neck osteotomy

The AMIS Mobile Leg Positioner enables the femoral neck osteotomy to be performed with a single-cut and with the femoral head in-situ. The femoral head extraction is much simpler.



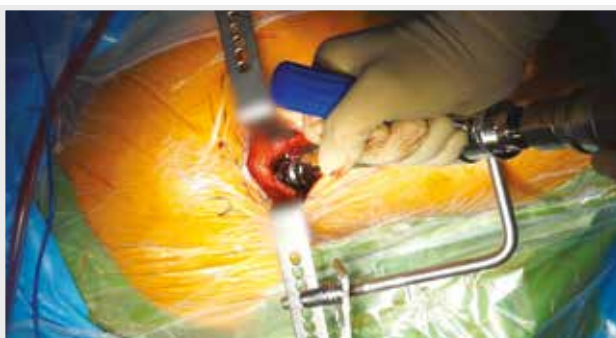By courtesy of Dr. Laude



By courtesy of Dr. Laude

Acetabular stage

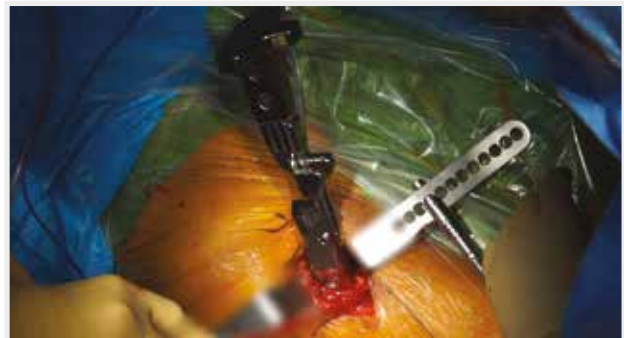Before starting the acetabular preparation the AMIS Charnley retractor is positioned on the capsular flap previously prepared (not on the muscle tissue). One good positioning of the AMIS Charnley retractor should be sufficient for the rest of the procedure. As it is a self-retaining retractor excessive use of other retractors is avoided, potentially reducing the risk of nerve or muscle damage^[5]. An offset reamer and cup impactor are used for acetabular preparation and cup placement.



By courtesy of Dr. Laude

Femoral stage

This step is where the AMIS Mobile Leg Positioner is most useful. It allows easy positioning of the femur to proceed with preparation and final femoral stem implantation by applying hyperextension, external rotation and adduction to the hip. Some capsular release might be needed. To prepare the femoral canal, Judet type broach handles are used.



By courtesy of Dr. Laude

Closure

Since there was no capsulotomy it is normally possible to conserve the capsular flap and to close it at the end.



Publication Review

Nowadays, the anterior approach is mainly used as a MIS technique (like the AMIS approach) and therefore many benefits are expected, such as shorter rehabilitation^[19,28-30] and faster return to daily activities^[27-29,31], decreased post-operative pain^[27,28,30], reduced risk of dislocation^[19], less blood loss^[26,28,30], a shorter hospital stay^[25-29], cosmetic appeal^[26,28,30] and also cost benefits^[32-35] to the surgeon/hospital. Through this Chapter we perform a review of:

- Publications regarding the minimally invasive anterior approach in general and the AMIS approach in particular, focusing on the associated clinical benefits.
- Comparative studies between the outcomes of a minimally invasive anterior approach and other approaches, to better understand the added value of the minimally invasive anterior approach.
- Publications reporting controversial results with the anterior approach, to understand if the AMIS can help avoid the controversial results presented.

Through this review we expect to clearly demonstrate that the AMIS approach for hip arthroplasty provides all the benefits expected from an MIS, not only in the short term, proving that this approach can effectively add value to a surgeon's practice and to hospitals worldwide.

MINIMALLY INVASIVE ANTERIOR APPROACH/AMIS PUBLICATION REVIEW

In literature, a large amount of evidence is found of the benefits that the minimally invasive anterior approach, and therefore the AMIS, provides.

Clinical benefits - Shorter rehabilitation and faster return to daily activities

The intermuscular and internervous path followed by the anterior approach should provide for a significantly shorter rehabilitation, which in turn means a faster return to daily activities. This was confirmed by Rachbauer in two studies, reporting that patients operated through a minimally invasive anterior approach experienced an accelerated rehabilitation with an early discharge^[26,30].

There are also AMIS publications which successfully report a faster rehabilitation. Dora provides evidence that the AMIS approach allowed to achieve better Harris Hip Score (HHS) 3 months after surgery, when compared to the lateral approach (91 vs 83)^[7]. Dallinger performed dynamic and isometric tests in a group of

27 patients, who underwent THA through the AMIS approach, to assess the abductor muscle strength on the leg and compared it with the abductor muscles strength from the contralateral side, which had previously undergone a THA through the lateral approach. The author concluded that using AMIS resulted in stronger abductor muscles. Dynamic tests indicated that the limb operated on by AMIS was stronger in 81% of the cases, while the isometric test showed better results in all abduction movements, with the AMIS side being stronger 78%, 81% and 75% of the times respectively at 0°, 10° and 20° of abduction. These results are more impressive if we consider that the AMIS-operated side had a short term recovery while the other limb presented a medium term recovery, which means that AMIS allows for a faster and more complete muscle strength rehabilitation^[43]. Sebecic et al reported a faster rehabilitation for the AMIS patients when compared to patients operated through the lateral approach^[36]. Nabavi et al assessed the outcomes of patients operated through the AMIS approach and compared them with the outcomes of patients operated through the posterior approach. Also here the AMIS showed better results. The mean postoperative HHS at 3 months was better for the AMIS group (85 vs 80) and it was reported that after 3 months 53% of the patients could walk an unlimited distance compared with only 28% of the patients operated through the posterior approach^[37,38]. Other publications acknowledge a faster recovery, and therefore an expected faster return to daily activities, when performing THA through the AMIS approach^[22,23,40,41,44,45,46,47,48,49,50].

Clinical benefits - Decreased post-operative pain

Reduced post-operative pain is expected in the case of less traumatic surgery as is the minimally invasive anterior approach. Rachbauer confirmed this in his studies where he assessed patient's outcomes resulting from the use of a minimally invasive anterior approach for primary THA. The author affirmed that those patients did not suffer from considerable postoperative pain^[26,30]. Sariali et al, who performed a prospective study including 1764 THA by a minimally invasive anterior approach, also stated that the patients who underwent the anterior approach did not experience much pain^[51].

Several authors also reported in their studies that patients operated through the AMIS approach suffered from less pain after surgery. Clayson reported an inferior consumption of morphine for patients operated by the AMIS approach against patients operated with the lateral approach^[47]; the same result has been obtained

by Sebecic et al^[36] and O'Donnell J^[48], who claimed a reduced demand for analgesics by the patients operated through the AMIS. Vasina et al also reported less pain for patients operated by the AMIS approach^[39].

Clinical benefits - Reduced risk of dislocation

As the anterior approach leaves the posterior structures implicated in hip instability intact, a reduced risk of dislocation is expected^[25]. Sariali et al performed a prospective study to evaluate the dislocation rate after THA using a minimally invasive anterior approach, in which 1764 consecutive primary THA through the anterior approach in 1374 patients were included. A dislocation rate of only 0.5% (when using 28 mm head diameter) was reported^[51]. Matta et al reported a dislocation rate of only 0.61% in a cohort of 437 patients (494 primary THA) operated through a minimal invasive anterior approach^[25], and Siguier et al reported a dislocation rate of 0.96% on a cohort of 1037 hips operated by a minimally invasive anterior access^[19]. Hoell et al actually reported zero dislocations in a series of 113 patients submitted to THA through the anterior approach (using heads bigger than 36 mm)^[52].

A reduced risk of dislocation is also observed in the AMIS publications. Laude, Vasina et al and Sebecic et al reported no dislocations on their series, and Jayankura et al reported only one dislocation (from 56 THA), in a patient that presented high risk factors for dislocation^[23,36,39,45,46].

Clinical benefits - Less blood loss

Due to the fact the anterior approach avoids damage to any major structures, a lower blood loss can be expected, together with a reduced risk of local complications and vein thrombosis^[22,23,24,40]. Rachbauer assessed patient's outcomes resulting from the use of a minimally invasive anterior approach for primary THA and confirmed the association between the anterior approach and reduced blood loss^[26,30].

AMIS publications do confirm it as well. Dora, in his study comparing the outcomes of his initial AMIS experience with the outcomes of patients operated by the lateral approach (both groups constituted by 100 patients), observed a less frequent need for blood transfusions when patients were operated by the AMIS approach (18 vs 37 transfusions performed)^[7]. Sebecic et al, who compared the outcomes obtained using AMIS against those obtained through the lateral approach (35 patients for both groups), also registered less blood loss when using the AMIS approach (490 ml vs 570 ml of mean blood loss)^[36]. Rahme et al reported in their study that patients undergoing hemiarthroplasty by the AMIS approach produced 12.5 g/L less blood loss than those operated by both lateral or posterior approach^[40]. Jakovljevic et al, who compared the results obtained with

AMIS against those produced by the posterior approach, also reported a significant reduction on blood loss when performing the AMIS approach (486 ml vs 736 ml)^[41]. Other publications also observed a reduced blood loss when performing THA through the AMIS^[39,42,47,53].

Clinical benefits - Shorter hospital stay

Several studies prove that with the anterior approach the patient hospitalization can be reduced. Matta et al reviewed a series of 437 consecutive, unselected patients who had 494 primary total hip arthroplasties performed through a MIS anterior approach. It was reported a mean hospital stay of only 3 days for patients having unilateral primary THA and 5 days for patients undergoing bilateral THA^[25]. Rachbauer, which assessed a prospective cohort study on 100 consecutive patients, also reported an early patient discharge^[26].

Reduced patient hospitalization is well proven also in AMIS specific publications. Dora reported a significantly shorter hospital stay when performing THA through the AMIS approach. He compared the results of his initial experience with the AMIS approach with his results achieved with the lateral approach. After 100 AMIS cases the mean hospital stay was already significantly shorter when AMIS was used (9 days vs 11 days), but it was even more evident after the following 150 cases (7 days vs 11 days)^[7]. Sebecic et al aimed to compare the outcomes of two groups of 35 patients, the former operated through the AMIS approach and the latter operated through the lateral approach. Again, the mean hospital stay was significantly reduced with the AMIS (10 days vs 12 days)^[36]. Nabavi et al presented evidence of reduced patient hospitalization after THA with the AMIS approach. Through a comparison between the results obtained during the author's initial experience with the AMIS approach (a group constituted by the first 50 patients operated with the AMIS) and those obtained through a posterior approach (a cohort of 70 patients), the author reports 8 days of mean hospital stay with the AMIS and 13 days for the posterior approach^[37,38]. Other studies also report a shorter hospital stay when the AMIS is used^[22,23,39,40,41,42]. In particular Bradley reported an average stay of only 2 days in 78% for 332 hips having THA through the AMIS^[42] and Laude reported that 50% of his patients could be discharged from the hospital after 2 days^[22,23].

Clinical benefits - Cosmetic appeal

The anterior approach does not involve damage to any major structure and for that reason can be considered a truly MI procedure. However, one of the major claims associated to MIS procedures is the cosmetic appeal, once they are associated with shorter incisions, typically less than 10 or 12 cm^[7]. In literature, authors who perform THA through a mini-invasive anterior approach report a

good feedback regarding the cosmetic appearance, with incisions being usually smaller than 10 cm^[19,25].

The AMIS approach also answers to that claim with incisions reported to be between 6.5-9 cm by Sebecic et al^[36] or 7-11 cm by Haaker et al^[54].

Economic benefits

The advantages inherent to the AMIS approach are mainly patient related, however patients are not the only ones who can benefit from an AMIS approach. In literature we can find evidence proving this statement. Actually, Greenhow presented a short review of the main articles that assess the economic impact related to the anterior approach, showing evidence of the additional value that an anterior approach can bring to a hospital, mainly related to saving costs achieved through the clinical and patient benefits (less blood loss, faster recovery, less rehabilitation, less pain), but it is also reported that the anterior approach allows an increase in the volume of the surgeon's practice^[68].

In detail, Christofilopoulos et al retrospectively compared a set of parameters (number of hospitalization days, average cost per case, operative time, destination of patient and number of hospital physiotherapy sessions) obtained when THA was performed through the AMIS approach (a group of 54 patients) with those obtained through the lateral approach (a group of 280 patients), to evaluate if the AMIS approach leads to a shorter hospital stay and diminished costs, as advocated. The results of this study were clear: the AMIS approach reduced all the parameters studied, i.e. the mean operative time (98 minutes vs 117 minutes), the number of intra-hospital physiotherapy sessions (3 vs 6), the mean hospital stay (7.1 days vs 11 days), and the average cost per case (13.554 CHF vs 21.000 CHF). Also, the AMIS allowed 80% of the patients to return directly home, while only half of the patients could do so when the lateral approach was used. This study demonstrated the economic potential that the AMIS can add to an hospital^[69,70].

The clinical benefits previously discussed, associated with the AMIS approach potentially allow for economic savings. The shorter hospitalization stay may provide additional profitability for the hospital, and may facilitate the post-operative management of the patient; due to AMIS, physical therapy is easier and the patient usually goes directly home allowing savings in rehabilitation costs; the reduced need for transfusions, cuts the costs per surgery; the reported decrease in postoperative pain will reduce drug delivery and therefore the associated costs; the risk of dislocation, which compromises the cost-effectiveness of a THR replacement, is reduced and therefore the associated costs are reduced as well; and it should be noted that AMIS allows improvement in

the efficiency of the operating team, because a surgeon can perform an AMIS with a minimal team, resulting in additional economic value.

One other aspect is that, currently, patients in need of THA are aware of what the AMIS approach represents and are actively requesting this approach. It has been verified that the AMIS allows an increase of surgeon's practice, with some surgeons doubling activity in only 2 years, after starting with the AMIS approach^[71]. This represents further evidence of the value added by the AMIS approach.

Not only short term advantages

It was shown that AMIS can effectively provide for clinical benefits. However, these are mostly said to be valuable only in a short-term when compared to standard approaches^[55]. Nowadays, literature shows evidence that the benefits of the AMIS approach are not exclusive to short term.

An article published on The Journal of Bone & Joint Surgery (Br) (now called The Bone & Joint Journal) by Dora C et al showed that at one year after surgery there is less symptomatic and asymptomatic muscle degeneration for patients operated using AMIS

compared with other conventional approaches^[56]. This means for the patients no residual trochanteric pain and limping in daily activities and advantages in the case of revision. Other studies have also confirmed these findings^[57,58,59].

Soft-tissue changes in hip abductor muscles and tendons after total hip replacement

Bremer AK, Kalberer F, Pfirrmann CWA, Dora C
J Bone Joint Surg (Br) 2011-July; 93-B:886-9.

Residual pain and damage to soft tissues after total hip replacement are strictly connected^[14]. This publication aims to compare, through MRI, the muscle and tendons damage produced by the AMIS approach compared to the transgluteal approach.

Two groups of patients underwent primary THR: 25 patients were operated through the AMIS approach, and the other 25 using a transgluteal approach. All patients underwent a post-operatively MRI at one year using the same 1.5-T system and protocol. The goal was to assess the presence of bursal fluid, the amount of damage to the abductor tendons and the grade of fatty atrophy of the abductor muscles.

Overall, the AMIS group presented significantly less alterations of the abductor structures. There was no register of full-thickness tears or detachments on the AMIS group while the control group presented them twice involving the tendon of gluteus minimus, and four times involving the lateral part of the gluteus medius. According to the odds ratio calculated, there was an increased risk seven times higher of abductor insertion alterations and an increased risk five times higher of collecting bursal fluid within the trochanteric region, when a transgluteal approach was used. The AMIS group displayed significantly less fatty atrophy of the gluteus medius and

gluteus minimus.

It is important to recognize that although many MR imaging findings such as altered signal intensity and abductor tendon diameter, bursal fluid collections, and fatty atrophy of the anterior gluteus minimus muscle are more frequent in symptomatic patients, they are also frequently found in asymptomatic patients after lateral transgluteal THR^[14].

These results confirm that the AMIS approach allows for less damage of the pelvitrochanteric muscles and tendons and no residual trochanteric pain and limping when compared to the transgluteal approach.

Revision through AMIS approach has been extensively investigated by Laude F et al in an article published in The Journal of Bone & Joint Surgery (Am)^[60]. Not only a preserved soft-tissue structure could be advantageous

in the case of revision, but also performing a revision surgery by preserving the soft tissues should bring additional advantages.

Revision Total Hip Arthroplasty Performed Through the Hueter Interval

Mast NH, Laude F
JBS Am. 2011; 93(Suppl.2):143-148.

Mast NH and Laude F investigate the possible benefits of anterior approach in case of complex or revision total hip arthroplasties, eventually using anterior approach extensions when needed. The study also evaluates the advantages of AMIS approach for the THR prior to revision. A consecutive series of fifty-one patients who underwent revision THR through the AMIS approach has been retrospectively reviewed, with a mean follow-up of 54.5 months (range of 8 to 160). The cases reported involve revision of acetabular components alone (41%), femoral components alone (2%), acetabular and femoral components (41%) and resurfacing systems (16%).

For all the revision cases reported, a good postoperative function was generally obtained (medium WOMAC score of 83), especially in case of revision of failed resurfacing systems (WOMAC>95). No post-operative dislocations have been reported.

A revision through the anterior approach after a primary posterior or anterolateral approaches can result in less scar removal during the approach, making the surgical procedure easier.

In case of primary total hip replacement performed through an anterior approach, the revision can potentially access through

the same anatomic path, preserving major structures of the hip joint and consequently allowing for possible quicker recovery.

An acetabular-only revision can usually be treated with a standard exposure for a primary anterior approach, with a similar post-operative recovery and rehabilitation process.

In conclusion, the study demonstrates that the anterior approach for revision THR provides advantages for the patient and for the surgeon. The anterior approach can be used for complex or revision THR with good outcomes in terms of WOMAC score and hip stability.

In one other publication, Laude addressed the same issue, but in French language^[61].

Difficult and revision cases through the anterior approach was one of the main themes on the 7th M.O.R.E. International Symposium. Various podium presentations assessed this matter, but the main conclusion was that the AMIS approach is not limited to straightforward primary surgeries, but it can also be used in difficult primary cases (such as dysplastic hips) and revision surgeries, allowing for potential benefits. During these lectures, descriptions of possible extension techniques of the AMIS approach and of different strategies for femoral/acetabular revisions were addressed, which covers nearly all hip arthroplasty cases^[62,63,64,65,66].

Cogan et al also assessed the benefits of performing revision surgeries through the anterior approach. Lower complication rates were reported when performing isolated cup revision cases^[67].

ANTERIOR APPROACH VS OTHER APPROACHES

Currently, MIS in hip arthroplasty is still a concept with no recognized unambiguous definition. It is suggested that the ideal MIS procedure should promote minimal tissue damage without cutting muscles and tendons so patients feel less pain and a significantly shorter rehabilitation with longer-term outcomes which are equal or better than a conventional approach^[72]. Considering this definition the only approaches considered truly minimally invasive are the mini antero-lateral or Röttinger approach (which follows an intermuscular plane between the TFL and the gluteus medius) and the minimally invasive anterior approach (which follows an intermuscular and an internervous plane: superficially between the sartorius - femoral nerve, and TFL – superior gluteal nerve, and deeper between the rectus femoris – femoral nerve, and gluteus medius – superior gluteal nerve^[9,73]), like the AMIS approach. The other so called minimal invasive variants, like the mini-lateral and mini-posterior, involve muscle section in spite of a smaller incision. However, it has been shown that the mini-anterolateral approach presents a high risk of damaging the superior gluteal nerve^[9,17].

Looking into the literature results most of the considered MIS procedures fail to demonstrate their benefits^[72], but the comparative studies between the minimally invasive anterior approach and other approaches found in literature tend to point to the minimally invasive anterior approach as the approach with better patient outcomes. Once the benefits of MIS are reported with the standard or MIS anterior approach and are not evident for other approaches, we used comparative studies between the anterior approach (standard or

MIS) and the other approaches (standard or MIS).

Anterior approach vs two-incision approach

The two-incision approach was introduced by Berger^[12] and his initial study gave the boost to the trend of the MIS in hip arthroplasty. However, other authors were not able to reproduce Berger's outcomes. The main problems reported were the high rates of complications and repeat surgery, because it was considered a technically demanding procedure^[11]. Indeed, this approach demands an anterior incision for the acetabular preparation and a posterior incision for the femoral preparation, which means that there will be muscle section (so it is not a true minimal invasive surgery to the hip)^[12].

The anterior approach uses only the anterior incision to perform the whole procedure, avoiding complications related to the posterior incision. The AMIS made the anterior approach straightforward and reproducible and the AMIS Education Program helps to avoid initial complications verified with the two-incision approach. No comparative studies between the anterior approach and the two-incision approach were found in literature.

Anterior approach vs posterior approach

The main problem reported by the posterior approach is hip dislocation, attributed to the posterior arthrotomy and mainly to the section of the external rotators group^[13]. This problem is maintained with the minimally invasive variant, because it doesn't avoid the referred sections^[8]. Actually, studies indicate that the mini-posterior approach has no advantages and introduces higher risk of complications when compared with the standard posterior approach^[8,10]. The anterior approach (standard or MIS) preserves the posterior structures that are important for preventing dislocation, highly reducing its risk^[19,23,36,39,45,46].

Looking into the studies which compared the AMIS approach with the posterior approach, Del Prete et al, who evaluated the systemic inflammatory response of patients operated through the AMIS approach against those operated through the posterior approach, concluded that the AMIS approach patients had lower post-operative levels of cytokines (mainly IL6), creatine kinase (CK), and C-reactive protein (CRP), which means there was less surgical trauma after the surgery. These patients also presented faster functional recovery, and less blood loss^[74]. Field et al, who performed a prospective, randomized study comparing the AMIS versus the posterior approach during their initial experience, reported a quicker functional recovery with patients operated through the AMIS approach, with a faster recovery by a week (in average)^[49,50,75]. Better recovery outcomes after using the AMIS approach was

also noticed by Kohan et al, who compared a sequential case series of the first 100 patients operated through the AMIS approach against 100 patients operated through the posterior approach. This study concluded that AMIS patients obtained higher scores (SF36v2 Total and Physical scores, WOMAC Total and Functional scores and HHS), especially in the 6 and 12 month intervals^[76,77]. Nabavi et al, when comparing a cohort of patients who underwent THA through the AMIS (50 patients) against those operated through the posterior approach (70 patients), showed that AMIS patients had a quicker recovery (lower CK levels on day one – 352 compared to 565, indicating less muscle damage, and an average HHS of 85 at 3 months against 80 for the posterior approach, $p=0.04$), 53% of them was able to walk an unlimited distance at 3 months, against only 28% for the posterior approach. In addition, AMIS patients had a shorter hospital stay (mean 8 days vs 13 days for the posterior approach)^[37,38].

Other comparative studies also demonstrate that the anterior approach (standard or MIS) produces better outcomes than the posterior approach (standard or MIS). Barrett et al performed a prospective, randomized clinical study to evaluate the benefits of the anterior approach (group of 43 patients) versus the posterior approach (group of 44 patients) for THA. Patients operated with the anterior approach presented better results not only in the immediate postoperative, with a better pain relief (VAS Pain Score - 4.0 vs 4.5) and bigger walking distances (on the day of surgery, then one and two days postoperative), but also at three months where patients showed better HHS results, which indicates an improved earlier function. In addition, the anterior approach patients were also discharged earlier from the hospital (mean hospital stay of 2.28 day vs 3.02 days)^[78]. Nakata et al demonstrated a faster recovery and shorter hospital stay when patients underwent THA through a minimally invasive anterior approach. The authors realized a consecutive series of 182 patients which were operated for THA by a minimally invasive anterior approach (99 hips) or by a mini-posterior approach (96 hips) and retrospectively compared the results of both groups. The patients who were operated by the minimally invasive anterior approach experienced a more rapid recovery of hip function and hip stability because these patients: were able to single-leg stance more than 5 seconds in less time (16.6 days vs 22.9 days), recovered from the Trendelenburg's sign faster (only 29% of the minimally invasive anterior approach presented positive Trendelenburg's sign after 3 weeks while there were 67% of the mini-posterior approach patients), required less time up to recognition of negative Trendelenburg's sign (16.7 days vs 24.8 days), needed less time to achieve walking with a single cane for more than 200 m (12 days vs 15.5 days), presented

more walking velocity at 3 weeks postoperatively (52.3 seconds vs 74.5 seconds to walk fifty-meters), needed less time to walk without the use of walking aids (at 3 weeks after operation 34% of the mini-anterior approach patients were able to walk without assistance while only 19% for the mini-posterior approach group) and presented a better ability to walk at 2 months postoperatively (Merle d'Aubigne and Postel scale of 5.0 for patients operated by the mini-anterior approach and 4.3 for the mini-posterior approach patients). Furthermore, the hospital stay was reduced by 8 days when the anterior approach was the chosen technique. To note that the authors reported also a greater implant positioning accuracy with the minimally invasive anterior approach (99% of the cups introduced by the mini-anterior approach were within the Lewinnek safe zone, 91% for the mini-PA79)^[80]. Similar results were also reported by Martin et al, who retrospectively compared 41 anterior and 47 posterior approach cases, reporting not only a shorter mean hospital stay when the anterior approach was used (2.9 vs 4.0 days) but also a faster rehabilitation, because the patients operated through the anterior approach needed fewer days to achieve an independent mobilization (2.4 vs 3.2 days). The authors concluded that the anterior approach promoted an early return to function and hospital discharge. In addition, it was also referred that the patients who underwent the anterior approach reported less pain^[3]. Zawadsky et al assessed the early outcomes of patients operated through the anterior approach comparing them against those obtained through the mini-posterior approach. Again, the anterior approach showed to be more effective, allowing for a reduction of the mean hospital stay of at least 1 day for the patients operated by the anterior approach. These patients also presented a bigger probability of being discharged directly to home instead of a rehabilitation center (80% vs 56%). An assessment of pain scores, mobility and use of pain drugs at 2 weeks and 6 weeks of follow up demonstrated that the anterior approach patients presented improved early clinical results: they presented less pain in both follow ups (VAS pain scores were reduced by 48% when the anterior approach was used), were less likely to be using pain killers (the medication was reduced by 49% when the anterior approach was used) and were more functional and mobile (at 2 weeks follow-up less than 20% of the anterior approach patients needed a walker compared to more than 74% of the posterior approach patients; at 6 weeks follow-up more than 80% of the patients operated through the anterior approach didn't need assistive devices against only 32% of the patients operated through the posterior approach)^[81]. Taunton et al realized a prospective randomized study also to examine the clinical differences between the anterior and the mini-posterior approach. This study showed evidence of a faster early functional

recovery when patients were operated through the anterior approach, once these patients showed a faster discontinuation of walking aids (median time of 22.8 days) when compared with those operated through the posterior approach (35.1 days)^[82]. Schweppe et al reported significant advantages on using the anterior approach when compared to the posterior approach. The patients operated through the anterior approach had less blood loss (285 vs 367 ml), needed less transfusions (18 vs 39 units) and needed less narcotics on the first postoperative days (101 vs 146 morphine equivalent dose). In addition, these patients had a quicker hospital discharge (70 vs 97 hours), and had a more favorable disposition (97% vs 84% discharged home). This study allowed two other conclusions: the thirty-day readmission rate was significantly lower for the anterior approach (1% vs 9%) and it produced better implant position (92% vs 70% of acetabular shells positioned in Lewinnek's safe zone)^[83]. On another study, Bergin et al prospectively compared the biochemical markers of muscle damage after THA of patients operated by the minimally invasive anterior approach against those operated by the mini-posterior approach, to evaluate the differences regarding local soft-tissue injury during THA. Knowing that a rise on creatine kinase (CK) is connected to muscle damage, this study indicated that the minimally invasive anterior approach induces less muscle damage than the mini-posterior approach, because there was a decrease 5.5 times lower of the CK level when the minimally invasive approach was used^[84]. The anterior approach shows an additional advantage when compared to the posterior approach: it allows the use of fluoroscopy. Rathod et al specifically evaluated the cup position obtained through a posterior approach (without fluoroscopy) against the cup position obtained through an anterior approach (with fluoroscopy). The "guided" anterior approach allowed a better precision on cup position (98% on cup inclination and 97% on cup anteversion) when compared to the posterior approach (86% on cup inclination and 77% on cup anteversion)^[85].

Anterior approach vs lateral approach

The lateral approach needs the detachment of the gluteus minimus (and a portion of the gluteus medius) from the greater trochanter^[73] which can lead to a delay in functional recovery and may be associated with residual trochanteric pain and limping^[14]. This problem is maintained with the mini-lateral approach because it follows the same path as the standard lateral approach, only through a mini-incision^[86], not having proved any added value^[87]. The anterior approach (standard or MIS) allows to save the previously referred structures to be saved potentially avoiding the associated problems^[7,44].

Regarding the comparative studies of the AMIS approach against the lateral approach, O'Donnell et al,

who performed a randomized control study comparing the outcomes of 20 patients operated through the AMIS approach against 20 patients operated with the lateral approach, reported that the AMIS patients had a faster functional recovery with better HHS results and presented significantly less pain (after 6 weeks and 1 year)^[48]. Rahme et al, who retrospectively compared the early postoperative outcomes in displaced proximal femoral fractures treated with hemiarthroplasty through different approaches (AMIS, lateral and posterior approach), demonstrated that patients operated through the AMIS approach can benefit from a reduced blood loss (less 12.5 g/L was produced per case when using AMIS) associated with lower transfusion rates, lower incidence of Deep Venous Thrombosis (DVT) and Pulmonary Embolisms (PE), and the AMIS patients took less time to walk 20 meters after their operation, having also a shorter hospitalization^[40].

Other comparative studies demonstrate a better soft-tissue response when the AMIS approach is used compared to the lateral approach^[14,56,58,59]. Alecci et al, which performed a retrospective study of 419 consecutive patients undergoing THA by the lateral approach (198 patients) or by a minimally invasive anterior approach (221 patients), reported an improvement of the results when using a minimally invasive anterior approach. The minimally invasive anterior approach patients presented less blood loss (3.1 g/dL vs 3.5 g/dL), needed less transfusions in the postoperative period (19.5% vs 40% of the patients), and experienced less postoperative pain (1.4 vs 2.5 mean NRS score). In addition, the minimally invasive anterior approach patients needed a shorter hospitalization (7 vs 10 days of mean hospital stay) and had a bigger probability to be discharged directly to home (58.4% vs 11.6%)^[88]. Restrepo et al prospectively assessed the functional outcomes of two randomized groups of 50 patients who underwent THA, one group was operated by the anterior approach and the other group was operated through the lateral approach. The authors demonstrated that the anterior approach provides for early functional recovery and for more satisfied patients when compared to the lateral approach, by evaluating different hip function measurements, like the HHS and the Lower Extremity Functional Score^[89]. One other study, performed by Ilchmann et al, also evaluated the improvements that the anterior approach can provide when compared to the lateral approach. This study assessed the postoperative clinical outcomes of two groups of patients who underwent THA, one group of 113 patients operated by a minimally invasive anterior approach and one other group of 142 patients operated by the mini-lateral approach. The reported outcomes demonstrated that patients operated by a minimally invasive anterior approach recovered faster than those operated by the mini-lateral approach, with more patients being able to independently get out of bed

and climb stairs after 7 days of surgery. The analysis of the clinical outcomes at 6 weeks, 12 weeks and 1 year follow-up enhances even more the perception of a faster recovery with the minimally invasive anterior approach, for the patients which underwent THA by this approach always presented significantly better outcomes for pain during movement, HHS and patient satisfaction. Besides, there were more anterior approach patients without any limping (47.3% vs 27.4% of the patients at 6 weeks; 70.5% vs 48.1% at 12 weeks; 87.7% vs 73.6% at 1 year) and they also had a shorter hospital stay (11 days vs 12 days)^[90]. Also Goebel et al demonstrated that the minimally invasive anterior approach allowed for faster recovery and shorter hospitalization. By performing a retrospective study comparing the outcomes of patients undergoing THA by the minimally invasive anterior approach or by the lateral approach (100 patients on each group), the authors showed that the patients with a mini-incision anterior approach needed shorter time to achieve a pre-defined therapeutic goal (6.4 days vs 7.4 days) and had a shorter hospital stay (mean hospital stay of 10.2 days vs 13.4 days). In addition, these patients needed less pain medication on the day of surgery (mean pain medication consumption of 19.6 mg vs 23.6 mg) and experienced less postoperative pain immediately after surgery (mean VAS score 1.6 vs 2.7) and on day one after surgery (mean VAS score 0.41 vs 0.66)^[91]. The minimally invasive anterior approach has shown to allow for a faster recovery when compared to the lateral approach also in a study performed by Torkos et al. On this prospective study, functional and life-quality changes in THA through a minimally invasive anterior approach and through a lateral approach were compared. It was reported an earlier mobilization and faster recovery thanks to the better HHS and EQ VAS scores obtained for patients undergoing THA by the minimally invasive anterior approach. Furthermore, it was reported that the abductor muscle strength was significantly greater for the minimally invasive anterior approach group. It should be also noted that the Trendelenburg-sign was detected in only 6.7% of the patients operated by the mini-invasive anterior approach, while it was present in 80% of the patients operated by the lateral approach^[92].

Anterior approach vs anterolateral (Röttinger or OCM) approach

The anterolateral approach, in spite of being an intermuscular approach goes directly through an innervated interval and its risk of nerve damaging is high and well documented^[93]. The mini-invasive solution of this approach has not solved this problem and the publications regarding it report a high risk of nerve damage^[9,15], TFL denervation^[16,17] and gluteus minimus fatty atrophy^[18]. As the anterior approach follows an intermuscular and internervous approach,

a reduced incidence of nerve and muscle damage is expected, and the preservation of hip abductors highly reduces the risk of Trendelenburg gait, commonly seen with the anterolateral approach^[94].

Clayson assessed the possible advantages of the AMIS approach when compared with the Röttinger approach. Having recognized the benefits of MIS procedures, he compared both these MIS variants for THA against his standard procedure in order to determine if these approaches could bring benefits in terms of patient outcomes after 1 year of follow up. While no differences were reported between the Hardinge and the Röttinger approach, the AMIS approach, when compared to the Hardinge approach, allowed not only a faster functional recovery of the patients (concluded by the better HHS and Merle d'Aubigné-Postel Score results) but also to better preserve the patient's abductors muscles (as concluded by the gait analysis performed). In addition, from the AMIS group more patients felt that the operated hip went back to feeling normal (70% - AMIS, 40% - Hardinge) indicating an increased patient satisfaction, there was less blood loss with the AMIS patients, they presented less pain after surgery as indicated by an inferior need of analgesics, and the costs associated with the AMIS approach were lower^[47].

From other publications, improved postoperatively function is reported with the anterior approach when compared with the anterolateral approach (standard or MIS). Bourne et al showed that using the anterior approach allows for improved function and reduced pain when compared to the anterolateral approach. When comparing the clinical and functional outcomes of 214 THA performed by the minimally invasive anterior approach (201 patients) with those of 259 THA performed through the anterolateral approach, it was shown that at 6 weeks of follow up the anterior approach patients presented better HHS (89 vs 72), less pain (Harris Hip pain score 40 vs 36) and better function (28 vs 17). These superior results were maintained at six months and 1 year of follow-up, and attention should be given to the fact that at one year postoperative only 5% of the patients operated through the anterior approach were sedentary or semi-sedentary, against 33% of the anterolateral approach patients^[94]. Same findings were reported by Renken et al. Comparing the early results obtained through a minimally invasive anterior approach with those obtained through the anterolateral approach after hemiarthroplasty, it was shown that the minimally invasive anterior approach allowed for earlier mobilization and reduced postoperative pain. A randomized study of 60 patients who underwent hemiarthroplasty, where 30 patients were operated through a minimally invasive anterior approach and 30 patients through the anterolateral approach, was

performed to compare the outcomes of these approaches. It was reported that patients operated through a minimally invasive anterior approach achieved not only better results regarding mobilization but also experienced less pain, especially after the 5th postoperative day^[95].

MINIMALLY INVASIVE ANTERIOR APPROACH - CONTROVERSIAL RESULTS

In spite of all the evidence in literature that proves the value of the anterior approach (MIS or standard), there are some studies that report controversial results when using this approach, especially related to complications during a surgeon's initial experience (the more experienced the surgeon, the lower the risk of complications^[96,97,98]). However, a closer look to those studies provides some possible explanations for the outcomes obtained.

Among the articles that report controversial results, many use an anterior approach technique without the assistance of a leg positioner^[98,99,100,101], which complicates the anterior approach procedure especially when exposing the femur^[23], possibly increasing the risk of complications, like damaging the TFL muscle^[102].

One other explanation that relates to those results might be the use of prostheses not so suitable to be implanted through the anterior approach^[103], like the Zweymüller type stem, which complicate the femoral preparation and might also increase the risk of complications.

One other interesting explanation for the not-so-good results is the fact that most of the studies assess a surgeon's initial experience with the anterior approach. Therefore, the outcomes reported are those obtained during the learning curve^[99,104], which is a period of adaptation to a new technique associated with added operative difficulty, reduced visualization and possibly increased operating time, drawbacks typical of a minimally invasive methods^[105]. One other important aspect that might explain the controversial results is a lack of appropriate surgeon education on the anterior approach previous to clinical practice^[105]. In fact, an appropriate education when changing approaches is considered essential in order to avoid complications^[106], and a lack of it will be related to an increased learning curve, so again it might contribute for an increased risk of complications.

Regarding the learning curve, a recent publication assessed its importance while changing to the anterior approach. This interesting study, performed by Müller et al^[96], reported that a senior surgeon who changes to a minimally invasive anterior approach might have a higher risk of complications on his first 20 cases

during the learning curve, but it normalizes after those cases. More importantly, it was demonstrated that junior surgeons trained with the anterior approach did not repeat the senior surgeon's learning curve. This means that appropriate teaching of junior surgeons can avoid mistakes by these new users, so surgeons who were appropriately trained by an experienced anterior approach user with the anterior approach are not expected to experience complications in their learning curve^[59].

With AMIS, surgeons won't be exposed to the referred possible sources of complications because the AMIS technique resorts to the use of the AMIS Mobile Leg Positioner, which eases a lot the surgery; Medacta has developed dedicated implants to facilitate the femoral preparation; and the AMIS offers an extended continuous Education Program to help avoiding possible complications, especially during the learning curve.

We include on this review one other article, not directly related to the anterior approach but very interesting

from a pain management point of view.

Local infiltration analgesia: a technique for the control of acute postoperative pain following knee and hip surgery

Kerr DR, Kohan L

Acta Orthop. 2008 Apr;79(2):174-83.

This publication by Kerr DR et al^[107] addresses a pain management technique following THA (and also total knee arthroplasty - TKA) named local infiltration analgesia (LIA), used with great success. The technique is described in detail throughout the publication, but summarizing, LIA consists of systematic infiltration of a mixture of ropivacaine, ketorolac, and adrenaline around the tissues subject to trauma to obtain a good pain management with little physiological

disturbance. This study consisted of an open, nonrandomized case series of 325 patients subjected to THA, TKA or hip resurfacing (HRA) where this LIA technique was used. The results indicated no serious side effects or complications directly attributable to the LIA technique and the pain scores measured (both at rest and while walking) were generally satisfactory as those collected after discharge. Also, no patients required morphine after postoperative day 1 and

generally, patients were discharged directly home after only one overnight stay in hospital. These results led to the conclusion that LIA is a simple, practical, safe and effective technique for pain management after hip and knee surgeries.

Discussion

This document has been produced to perform a review of the studies regarding the anterior approach published in literature, including those realized on the AMIS approach, in order to demonstrate the important advantages of using it for THA. After performing the publication review it can be affirmed that the goal was achieved.

Throughout this document it was demonstrated that performing THA through the AMIS effectively brings important advantages. It was shown that it allowed for important clinical benefits, like shorter rehabilitation and faster return to daily activities, decreased post-operative pain, reduced risk of dislocation, less blood loss, a shorter hospital stay, and a highly cosmetic appeal coming from a smaller incision. These benefits allow not only for improved patient wellbeing, but are also directly linked to potential cost benefits to the surgeon/hospital, as shown. The shorter rehabilitation time makes physical therapy easier and cheaper and allows patient to return faster to daily activities, the reduced post-operative pain allows a reduction of drug delivery and related costs, the reduced risk of dislocation reduces the costs associated with other related treatments, the reduced blood loss reduces the cost inherent to blood transfusion and the shorter hospitalization provides additional profitability for the hospital. Moreover, it was shown that the clinical advantages coming with the AMIS approach can be expected not only in the short term, as AMIS induces less muscle and nerve damage and therefore a noticeable reduction of muscle degeneration and fatty atrophy in a medium term can be expected.

With regard to potential added value that the AMIS approach can provide, it is important to note that nowadays, patients are more aware and informed about an approach that produces better hip replacement outcomes and are asking for the AMIS procedure. Actually, it has been verified that the AMIS allows an increase of surgeon/hospital's activity, with some surgeons/hospitals being able to double their activity in only 2 years after starting with the AMIS approach^[71]. It is important to point out that the special AMIS instrumentation and the M.O.R.E. AMIS Education Program do not involve any additional costs to the surgeon/hospital, and that the AMIS approach can be performed by a surgeon with minimal staff, improving the efficiency of the operating team and also reducing the associated costs.

Furthermore, the comparative studies between the anterior approach and other approaches presented repeatedly demonstrated that the anterior approach was

more effective. However, some controversial results are reported on literature. These were assessed in order to understand possible explanations. It was concluded that performing the anterior approach technique without a leg positioner, using bulky femoral stems and not having an appropriate specific training, are probable reasons behind these controversial results. AMIS positively addresses these possible problems, so surgeons' exposure to the referred sources of complications is lower.

AMIS is not only a surgical technique, but a complete set of services for a surgeon who wants to perform the anterior approach, including ongoing medical education, dedicated implants and instruments. Over the last 10 years, the M.O.R.E. AMIS Education Program has enabled successful diffusion of the AMIS approach all over the world and made Medacta the "Best in Class" on anterior approach education. It benefits from a strong commitment to continue evolving always in the direction of providing the best support, the best solutions and maintain efforts to add value to surgical practices around the world.

References

1. Rachbauer F, Kain MSH, Leunig M. The History of the Anterior Approach to the Hip. *Orthop Clin N Am*, 40:311-320, 2009.
2. Kreuzer S, Matta JM. Single-incision anterior approach for total hip arthroplasty: Smith-Petersen approach. O'Connor MI, Griffin LY, eds., *Limited Incisions for Total Hip Arthroplasty*, AAOS, Rosemont, 1-14, 2007.
3. Martin CT, Pugely AJ, Gao Y, Clark CR. A comparison of hospital length of stay and short-term morbidity between the anterior and the posterior approaches to total hip arthroplasty. *J Arthroplasty*. 2013 May;28(5):849-54.
4. Hueter C. Fünfte abtheilung: die verletzung und krankheiten des hüftgelenkes, neunundzwanzigstes capitel. In: Hueter C, editor. *Grundriss der chirurgie*. 2nd edition. Leipzig: FCW Vogel; 1883. P. 129-200.
5. Matta JM. Anterior approach for total hip replacement: background and operative technique, in Scuderi GR, Tria AJ, Berger RA (eds): *MIS Techniques in Orthopaedics*. Berlin, Springer Science & Business Media Inc, 2005, pp 121-140.
6. Judet J, Judet H. Voie d'abord antérieure dans l'arthroplastie totale de la hanche. *Presse Méd* 1985; 14: 1031-3.
7. Dora C. Minimalinvasive Zugänge an der Hüfte. *Orthopädie Mitteilungen* 6/07, 574-576.
8. Ogonda L, Wilson R, Archbold P, Lawlor M, Humphreys P, O'Brien S, Beverland D. A minimal-incision technique in total hip arthroplasty does not improve early postoperative outcomes: a prospective, randomized, controlled trial. *J bone Joint Surg Am* 2005; 87(4):701-10.
9. Ince A, Kemper M, Waschke J, Hendrich C. Minimally invasive anterolateral approach to the hip. Risk to the superior gluteal nerve. *Acta Orthopaedica* 2007; 78 (1):86-89.
10. Woolson ST, Mow CS, Syquia JF, Lannin JV, Schurman DJ. Comparison of primary total hip replacements performed with a standard incision or a mini-incision. *JBJS Am* 2004 Jul, 86-A(7):1353-8.
11. Bal BS, Haltom D, Aleto T, Barrett M. Early Complications of Primary THR Performed with a two-incision Minimally Invasive Technique; *J Bone Joint Surg Am* 87: 2432-2438, 2005.
12. Berger R. Total hip arthroplasty using the minimally invasive two-incision approach. *Clin Orthop Relat Res*, 417: 232-241, 2003.
13. Werner BC, Brown TE. Instability after total hip arthroplasty. *World J Orthop* 2012 August 18; 3(8): 122-130.
14. Pfirrmann CWA, Notzli HP, Dora C, Hodler J, Zanetti M. Abductor tendons and muscles assessed at MR Imaging after total hip arthroplasty in asymptomatic and symptomatic patient. *Radiology* 2005; 235:969-976.
15. T Stähelin. Abductor repair failure and nerve damage during hip replacement via the transgluteal approach: Why less invasive methods of joint replacement are needed, and some approaches to solving the problems. *Orthopäde*, 5(12):1215-24, 2006.
16. T Stähelin et al. Tensor denervation and little abductor damage from hip replacement with the Röttinger technique; *Schweiz Med Forum* 2006, 6: (Suppl.32)
17. Unis DM, Benitez C, Friedmann P. MRI Assessment of Tensor Fascia Lata after modified Anterolateral Total Hip Arthroplasty.; AAOS 2010 Proceedings, 9th-13th March, New Orleans.
18. Müller M, Tohtz S, Winkler T, Dewey M, Springer I, Perka C. MRI findings of gluteus minimus muscle damage in primary total hip arthroplasty and the influence on clinical outcome. *Arch Orthop Trauma Surg*. 2010 Jul;130(7):927-35.
19. Siguier T, Siguier M, Brumpt B. Mini-incision anterior approach does not increase dislocation rate: a study of 1037 consecutive total hip replacements. *Clin Orthop Relat Res* 2004; 426: 164-73.
20. Matta JM, Ferguson TA. The anterior approach for hip replacement. *Orthopedics*. 2005 Sep;28(9):927-8.
21. Chechik O, Khashan M, Lador R, Salai M, Amar E. Surgical approach and prosthesis fixation in hip arthroplasty world wide. *Arch Orthop Trauma Surg*. 2013 Nov;133(11):1595-600.
22. Laude F, Moreau P, Vié P. Arthroplastie totale de hanche par voie antérieure de Hueter mini-invasive. *Maîtrise Orthopédique* 2008(179):6-11.
23. Laude F. Total hip arthroplasty through an anterior Hueter minimally invasive approach. *Interact Surg* (2006) 1: 5-11.
24. Lesur E, Laude F. The minimally invasive trend in total hip arthroplasty through the anterior approach. *Encyclopédie Médico-Chirurgicale* (2004) 44-667-B.
25. Matta JM, Shahrdar C, Ferguson T. Single-incision anterior approach for total hip arthroplasty on an orthopaedic table. *Clin Orthop Relat Res*, 2005 Dec, (441): 115-24.
26. Rachbauer F. Minimally Invasive total hip arthroplasty via direct anterior approach. *Orthopäde*, 2005 Nov, 34 (11): 1103-4, 1106-8, 1110.
27. Huo MH, Gilbert NF. What's new in hip arthroplasty. *JBJS Am*; 2005 Sep, 87(9):2133-46.
28. Hartzband MA. Posterolateral minimal incision for total hip replacement: technique and early results. *Orthop Clin North Am*, 2004 Apr; 35(2):119-29.
29. Berger RA, Jacobs JJ, Meneghini RM, Della Valle C, Paprosky WV, Rosenberg AG. Rapid Rehabilitation and recovery with minimally invasive total hip arthroplasty. *Clin Orthop Relat Res*, 2004, (429): 239-247.
30. Rachbauer F. Minimally Invasive total hip arthroplasty: anterior approach. *Orthopäde*, 2006 Jul;35(7):723-4, 726-9.
31. Kennon RE, Keggi MJ, Keggi KJ. The minimally invasive anterior approach to hip arthroplasty. *Orthopäde*, 2006 Jul, 35 (7): 731-7.
32. Straumann D, Valderabano V, Eckstein M, Dick W, Dora C. Cost benefit analysis of MIS THA: Model-based analysis of the consequences for Switzerland. *Hip International*, Vol 16 no 2 (suppl 4), 2006/ pp S54-S57.
33. Bertin KC. Minimally Invasive outpatient total hip arthroplasty: a financial analysis. *Clin Orthop Relat Res*, 2005 Jun, (435): 154-63.
34. Sanchez-Sotelo J, Haidukewych GJ, Boberg CJ. Hospital cost of dislocation after primary total hip arthroplasty. *JBJS Am*, 2006 Feb, 88(2):290-4.
35. Schürmann N, Müller RT. Primary hip- and knee arthroplasty-comparison of the actual costs with the Australian diagnosis related groups (DRG)-. *Z Orthop Ihre Grenzgeb*. 2002 Nov/Dec;140(6):589-94.
36. Sebecic B, Staresinic M, Culjak V, Japjec M. Minimally invasive hip arthroplasty: advantages and disadvantages. *Med Glas Ljek komore Zenicko-dobojsk kantona* 2012; 9(1):160-165.
37. Nabavi A, Philibert S, Morizzi R. A prospective study comparing short term results of anterior minimally invasive hip replacement surgery with the standard posterior approach. Poster at the 86th Annual Meeting of the JOA, Hiroshima, Japan, May 23-26, 2013.
38. Nabavi A, Philibert S, Olwill C. A prospective study comparing short term results of direct anterior hip replacement surgery with the posterior approach. Podium Presentation at the 73rd Annual Scientific Meeting of the AOA, Darwin, Australia, October 6-9, 2013.
39. Vasina PG, Rossi R, Giudice GM, Palumbi P. Hip arthroplasty through the anterior minimally invasive approach. *Sphera* 2010;6(12) - Speciale Ortopedia.
40. Rahme DM, Millar MJ. Early postoperative outcomes in displaced intracapsular proximal femoral fractures treated with hemiarthroplasty. A retrospective comparison of surgical approaches. Podium Presentation at the 73rd Annual Scientific Meeting of the AOA, Darwin, Australia, October 6-9, 2013.

41. Jakovljevic A, Grubor P, Domuzin M, Vlatkovic D, Maran M, Kalacun D, Perisic S. Amis versus posterior MIS in THA. Podium Presentation at the 9th Domestic Meeting of the EHS, Athens, Greece, September 9-11, 2010.
42. Bradley G. C-arm guided triple taper HA-coated direct anterior THA. Podium Presentation at the 26th Annual Congress of ISTA, Palm Beach, Florida, October 16-19, 2013.
43. Dallinger R. Post-operative isokinetic strength measurements for various hip approaches. Podium presentation at the 1st World Conference on Anterior Hip Approach, Zurich, Switzerland, September 10-12, 2009.
44. Dora C. Der anteriore Zugang für die minimal-invasive HTPE. *Leading Opinions, Orthopädie* 1, 2006.
45. Jayankura M, Potaznik A, Roty M, Rooze M, Remy P, Biltiau N, Gillard B, Schuind F. Early recovery after total hip arthroplasty implanted by mini invasive direct anterior approach: isokinetic and isometric muscle strength analyse. Podium presentation at the 6th Annual International Conference SICOT, Pattaya, Thailand, 29 October – November 1, 2009.
46. Jayankura M, Roty M, Potaznik A, Rooze M, Cermak K, Remy P, Gillard B, Biltiau N, Schuind F. Isokinetic and isometric muscle strength recovery after total hip arthroplasty implanted by direct anterior approach. Podium presentation at the 10th Annual Congress of the EFORT, Vienna, Austria, June 3-6, 2009.
47. Clayson P. AMIS vs Röttinger approach. Podium presentation at the 6th M.O.R.E. International Symposium on total hip and knee replacement, Stresa, Italy, May 13-14, 2011.
48. O'Donnell J. A randomized controlled trial of anterior vs Hardinge approach for THR. Podium presentation at the Annual Scientific Meeting of the Arthroplasty Society of Australia, Gold Coast, Australia, June 1 – 4, 2011.
49. Yeo A, Strambi F, Buly J, Hisole J, Field RE. Prospective randomised trial comparing anterior versus posterior approach for total hip arthroplasty. Poster at the Annual Scientific Meeting of the BHS, Manchester, England, 29 February - 2 March, 2012.
50. Yeo A, Buly J, Hisole J, Strambi F, Field RE. Prospective, randomised trial comparing anterior versus posterior approach for total hip arthroplasty. Poster at the 13th Annual Congress of the EFORT, Berlin, Germany, May 23-25, 2012.
51. Soriali E, Leonard P, Mamoudy P. Dislocation after total hip arthroplasty using Hueter anterior approach. *J Arthroplasty*. 2008 Feb;23(2):266-72.
52. Hoell S, Sander M, Gosheger G, Ahrens H, Dieckmann R, Hauschild G. The minimal invasive direct anterior approach in combination with large heads in total hip arthroplasty – is dislocation still a major issue? A case control study. *BMC Musculoskelet Disord*. 2014 Mar 12;15:80.
53. Walcher T. Minimal invasive prosthetics for femoral neck fractures. *Leading Opinions Orthopädie* 2/2010: 16-19.
54. Haaker R, Wojciechowski M, Viebahn R, Gruber G. Der direkt anteriore minimalinvasive Zugang (AMIS) mit extensionshilfe und Navigation. *Medizinisch Orthopädische Technik* – 2007(5):7-13
55. Wall SJ, Mears SC. Analysis of published evidence on minimally invasive total hip arthroplasty. *J Arthroplasty*. 2008 Oct;23(7 Suppl):55-8.
56. Bremer AK, Kalberer F, Pfirrmann CWA, Dora C. Soft-tissue changes in hip abductor muscles and tendons after total hip replacement: Comparison between the direct anterior approach and the transgluteal approaches approaches. *J Bone Joint Surg [Br]* 2011-July; 93-B:886-9.
57. Dora C, Bremer A, Kalberer F, Pfirrmann C. Muscular damage after total hip arthroplasty: conventional versus minimally invasive anterior approach. Podium Presentation at the 68th Annual Scientific Meeting of the AOA 2008, Hobart, Australia, October 12-16, 2008.
58. C Dora, C Pfirrmann, H Nötzli, J Hodler, M Zanetti. MR imaging of the abductor tendons and muscles after total hip replacement in asymptomatic and symptomatic patients. *EFORT* 2007, Italy, Florence, 11-15 May 2007.
59. Zing P. AMIS using Versafitcup and Quadra to overcome tissue response: 5-year results. Podium Presentation at the 7th M.O.R.E. International Symposium, Lugano, Switzerland, April 11-12, 2014.
60. Mast NH, Laude F. Revision total hip arthroplasty performed through the Hueter interval. *J Bone Joint Surg Am*. 2011; 93:143-148.
61. Laude F. Les revisions de prothèse totale de hanche par voie antérieure. *Maitrise Orthopédique*, Novembre 2014 (238):20-25.
62. Laude F, Costa V. Difficult cases through AMIS. Podium Presentation at the 7th M.O.R.E. International Symposium, Lugano, Switzerland, April 11-12, 2014.
63. Oinuma K, Tamaki T, Miura Y, Shiratsuchi H. Dysplastic cases through anterior approach. Podium Presentation at the 7th M.O.R.E. International Symposium, Lugano, Switzerland, April 11-12, 2014.
64. Faldini C. Strategies for acetabular revision. Podium Presentation at the 7th M.O.R.E. International Symposium, Lugano, Switzerland, April 11-12, 2014.
65. Rodriguez J. Strategies for femoral revision. Podium Presentation at the 7th M.O.R.E. International Symposium, Lugano, Switzerland, April 11-12, 2014.
66. Matta JM. Revision surgeries through anterior approach. Podium Presentation at the 7th M.O.R.E. International Symposium, Lugano, Switzerland, April 11-12, 2014.
67. Cogan A, Klouche S, Mamoudy P, Soriali E. Total hip arthroplasty dislocation rate following isolated cup revision using Hueter's direct anterior approach on a fracture table. *Orthop Traumatol Surg Res*. 2011 Sep;97(5):501-5.
68. Greenhow R. Economical impact of AMIS & other new technologies in THR. Podium Presentation at the 7th M.O.R.E. International Symposium, Lugano, Switzerland, April 11-12, 2014.
69. Christofilopoulos P, Roussos C, Lädermann A, Lübbecke A, Hoffmeyer P. Socioeconomic aspects of total hip arthroplasty. A comparison between anterior minimally invasive surgery and standard lateral approach. Poster at the 12th EFORT Congress, Copenhagen, Denmark: 1-4 June 2011.
70. Roussos C, Christofilopoulos P, Lädermann A, Lübbecke A, Hoffmeyer P. Socioeconomic aspects of total hip arthroplasty. A comparison between anterior minimally invasive surgery and standard lateral approach. Presentation at the 70th Annual Congress of the SSOT, St. Gallen, 30.06-02.07.2010.
71. Data on file: Medacta.
72. Smith TO, Blake V, Hing CB. Minimally invasive versus conventional exposure for total hip arthroplasty: a systematic review and meta-analysis of clinical and radiological outcomes. *Int Orthop*. 2011 Feb;35(2):173-84.
73. Kelmanovich D, Parks ML, Sinha R, Macaulay WV. Surgical approaches to total hip arthroplasty. *Journal of the Southern Orthopaedic Association* 12(2):90-94, 2003.
74. Del Prete F, Manfredi M, Petrini A, Colpo M. Quantification of surgical trauma: comparison of posterolateral and anterior minimally invasive (AMIS) surgical approach for Total Hip Arthroplasty based on inflammatory markers (interleukins). Preliminary report. 11th Congress of the EHS, Stockholm, Sweden, 9-11 October 2014.
75. Field R, Yeo A, Buly J, Dinneen A, Strambi F, McLatchie W. Prospective randomized controlled clinical trial comparing THA performed either through a posterior approach or AMIS using gait analysis. Podium Presentation at the 7th M.O.R.E. International Symposium, Lugano, Switzerland, April 11-12, 2014.
76. Kohan L, Field C, Kerr D. Comparison between anterior and posterior approaches for total hip replacement. Combined AOA/NZOA Scientific Meeting, Rotorua, New Zealand, 9-11 October 2011.
77. Kohan L, Field C, Farrah S, Nguyen D, Kerr D. Comparison between anterior and posterior approaches for THA. Podium Presentation at the 7th M.O.R.E. International Symposium, Lugano, Switzerland, April 11-12, 2014.
78. Barrett WVP, Turner SE, Leopold JP. Prospective randomized study of direct anterior vs postero-lateral approach for total hip arthroplasty. *J Arthroplasty*. 2013 Oct;28(9):1634-8.
79. Lewinnek GE, Lewis JL, Tarr R, Compere CL, Zimmerman JR. Dislocations after total hip-replacement arthroplasties. *J Bone Joint Surg Am*. 1978 Mar;60(2):217-20.
80. Nakata K, Nishikawa M, Yamamoto K, Hirota S, Yoshikawa H. A clinical comparative study of the direct anterior with mini-posterior approach. *J Arthroplasty*; 24(5):698-704, 2009.

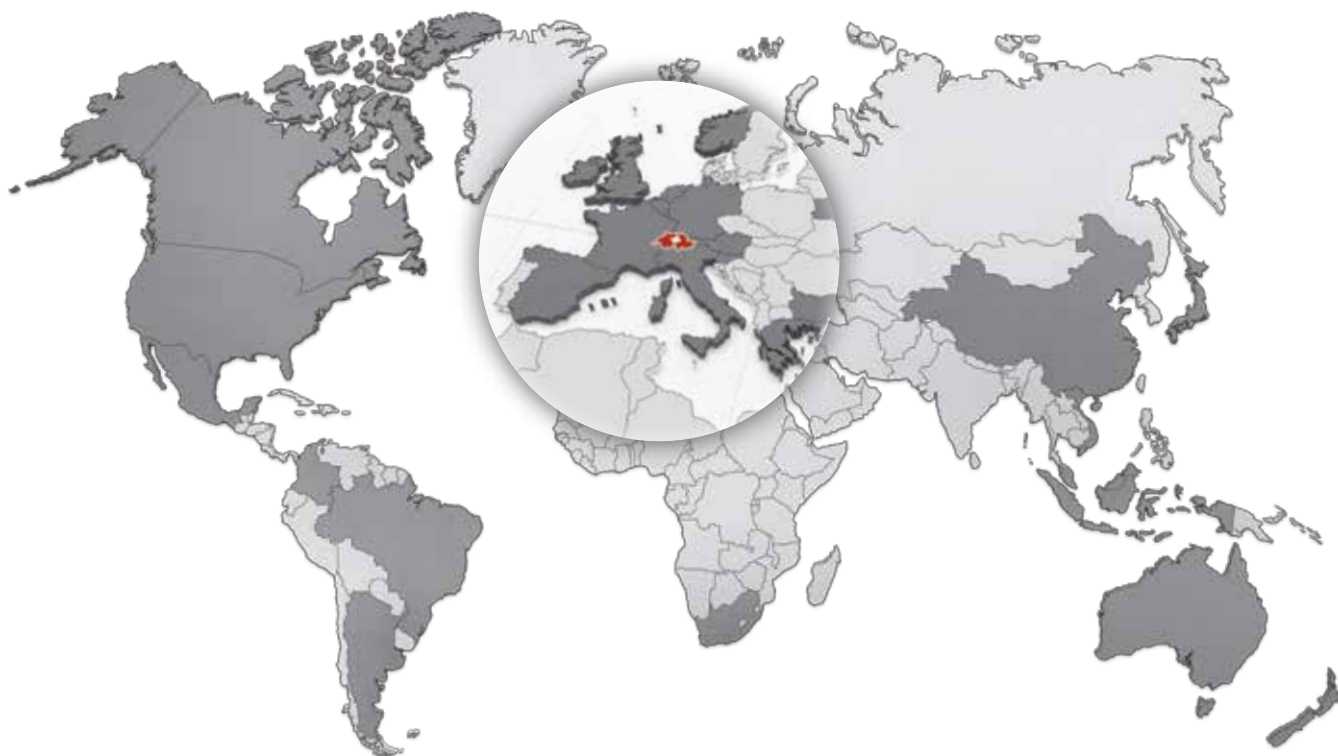81. Zawadsky MW, Paulus MC, Murray PJ, Johansen MA. Early Outcome Comparison Between the Direct Anterior Approach and the Mini-Incision Posterior Approach for Primary Total Hip Arthroplasty: 150 Consecutive Cases. *J Arthroplasty*. 2013 Dec 1.
82. Taunton MJ, Mason JB, Susan MO, Springer BD. Direct anterior total hip arthroplasty yields more rapid voluntary cessation of all walking aids: a prospective, randomized clinical trial. *J Arthroplasty*. 2014 Sep;29(9 Suppl):169-72.
83. Schweppe ML, Seyler TM, Plate JF, Swenson RD, Lang JE. Does surgical approach in total hip arthroplasty affect rehabilitation, discharge disposition, and readmission rate? *Surg Technol Int*. 2013 Sep;23:219-27.
84. Bergin PF, Doppelt JD, Kephart CJ, Benke MT, Graeter JH, Holmes AS, Haleem-Smith H, Tuan RS, Unger AS. Comparison of minimally invasive direct anterior versus posterior total hip arthroplasty based on inflammation and muscle damage markers. *J Bone Joint Surg Am*. 2011 Aug 3;93(15):1392-8.
85. Rathod PA, Bhalla S, Deshmukh AJ, Rodriguez JA. Does fluoroscopy with anterior hip arthroplasty decrease acetabular cup variability compared with a nonguided posterior approach? *Clin Orthop Relat Res*. 2014 Jun;472(6):1877-85.
86. O'Brien DA, Rorabeck CH. The mini-incision direct lateral approach in primary total hip arthroplasty. *Clin Orthop Relat Res*. 2005 Dec;441:99-103.
87. de Beer J, Petruccioli D, Zalzal P, Winemaker MJ. Single-incision, minimally invasive total hip arthroplasty: length doesn't matter. *J Arthroplasty*. 2004 Dec;19(8):945-50.
88. Alecci V, Valente M, Crucil M, Minerva M, Pellegrino CM, Sabbadini DD. Comparison of primary total hip replacements performed with a direct anterior approach versus the standard lateral approach: perioperative findings. *J Orthop Traumatol*. 2011 Sep;12(3):123-9.
89. Restrepo C I, Parvizi J, Pour AE, Hozack WJ. Prospective randomized study of two surgical approaches for total hip arthroplasty. *J Arthroplasty*. 2010 Aug;25(5):671-9.
90. Ilchmann T, Gersbach S, Zwicky L, Clauss M. Standard Transgluteal versus Minimal Invasive Anterior Approach in hip Arthroplasty: A Prospective, Consecutive Cohort Study. *Orthop Rev (Pavia)*. Dec 2013; 5(4): e31.
91. Goebel S, Steinert AF, Schillinger J, Eulert J, Broscheit J, Rudert M, Nöth U. Reduced postoperative pain in total hip arthroplasty after minimal-invasive anterior approach. *Int Orthop*. 2012 Mar;36(3):491-8.
92. Torkos M, Gimesi C, Toth Z, Bajzik G, Magyar A, Szabo I. Comparative Results of half year follow-up after primary total hip arthroplasty with minimally invasive anterior and direct lateral approach. *J Bone Joint Surg Br* 2012 vol. 94-B no. SUPP XXXVII 124.
93. Palan J, DPhil DJB, Murray DW, Andrew JG, Nolan J. Which Approach for Total Hip Arthroplasty Anterolateral or Posterior? *Clin Orthop Relat Res* (2009) 467:473-477.
94. Bourne MH, Mariani EM. A Comparison Between Direct Anterior Surgery of the Hip (DASH) and the Anterolateral (AL) Surgical Approach to Total Hip Arthroplasty: Postoperative Outcomes. *AAOS 2010 Proceedings*, 9th-13th Mar, New Orleans.
95. Renken F, Renken S, Paech A, Wenzl M, Unger A, Schulz AP. Early functional results after Hemiarthroplasty for femoral neck fracture: a randomized comparison between a minimal invasive and a conventional approach. *BMC Musculoskeletal Disorders* 2012 13:141.
96. Müller DA, Zingg PO, Dora C. Anterior minimally invasive approach for total hip replacement: five-year survivorship and learning curve. *Hip Int* 2014.
97. Post ZD, Orozco F, Diaz-Ledezma C, Hozack WJ, Ong A. Direct anterior approach for total hip arthroplasty: indications, technique, and results. *J Am Acad Orthop Surg*. 2014 Sep; 22(9):595-603.
98. Hartog YM, Mathijssen NM, Peters SJ, Vehmeijer SB. The anterior supine intermuscular approach for total hip arthroplasty: reducing the complication rate by improving the procedure. *Hip Int*. 2014 Sep 1.
99. Spaans AJ, van de Hout JAAM, Bolder SBT. High complication rate in the early experience of minimally invasive total hip arthroplasty by the direct anterior approach. *Acta Orthop*. 2012 Aug;83(4):342-6.
100. D'Arrigo C, Speranza A, Monaco E, Carcangiu A, Ferretti A. Learning curve in tissue sparing total hip replacement: comparison between different approaches. *J Orthop Traumatol*. 2009 Mar;10(1):47-54.
101. Hallert O, Li Y, Brismar H, Lindgren U. The direct anterior approach: initial experience of a minimally invasive technique for total hip arthroplasty. *J Orthop Surg Res*. 2012 Apr 25;7:17.
102. Frye BM, Berend KR, Lombardi AV Jr, Morris MJ, Adams JB. Do sex and BMI predict or does stem design prevent muscle damage anterior supine minimally invasive THA? *Clin Orthop Relat Res*. 2014 Oct 22.
103. Jewett BA, Collis DK. High complication rate with anterior total hip arthroplasties on a fracture table. *Clin Orthop Relat Res*. 2011 Feb;469(2):503-7.
104. Woolson ST, Pouliot MA, Huddleston JI. Primary total hip arthroplasty using an anterior approach and a fracture table: short-term results from a community hospital. *J Arthroplasty*. 2009 Oct;24(7):999-1005.
105. Berry DJ, Berger RA, Callaghan JJ, Dorr LD, Duwelius PJ, Hartzband MA, Lieberman JR, Mears DC. Minimally invasive total hip arthroplasty. Development, early results, and a critical analysis. *J Bone Joint Surg Am*. 2003 Nov;85-A(11):2235-46.
106. Ajouy K, Bocquet D. Maitrise Orthopédique, Octobre 2013 [227]:24-27.
107. Kerr DR, Kohan L. Local infiltration analgesia: a technique for the control of acute postoperative pain following knee and hip surgery. *Acta Orthop*. 2008 Apr;79(2):174-83.



HOLISTIC

PRECISE

EFFICIENT



medacta.com

Headquarters

Medacta International SA

Strada Regina - 6874 Castel San Pietro - Switzerland
Phone +41 91 696 60 60 - Fax +41 91 696 60 66 - info@medacta.ch

Representative

Switzerland - Frauenfeld

Gewerbestrasse 3 - 8500 Frauenfeld
Phone +41 (0) 848 423 423 - Fax +41 (0) 848 423 424 - info@medacta-swiss.ch

Subsidiaries

Australia - Medacta Australia PTY.LTD

Unit A1, 16 Mars Road - Lane Cove - NSW 2066
Phone +61 (2) 94202944 - Fax +61 (2) 94202578 - info@medacta.com.au

Belgium - Medacta Belgium B.V.B.A./S.P.R.L.

5a Rue de la Maîtrise - 1400 Nivelles
Phone +32 (0) 67 555 482 - Fax +32 (0) 67 555 483 - info@medacta.be

Canada - Medacta Canada Inc.

31 McBrine Drive, Unit 11- N2R 1J1 - Kitchener, Ontario
Phone +1 519 279 1934 - Fax +1 519 279 1938 - info@medacta.ca

China - Medacta China

Room B, 32/F, New SH Intl Tower - No. 360 Pudong South Road - Shanghai 200120, China
Phone +86 21 5835 1149 - info@medacta.cn

France - Medacta France SAS

6 Rue du Commandant d'Estienne d'Orves - Parc des Chanteraines - 92390 Villeneuve - La Garenne
Phone +33 147 39 07 22 - Fax +33 147 39 73 17 - info@medacta.fr

Germany - Medacta Ortho GmbH

Jahnstrasse 86 - D - 73037 Göppingen
Phone +49 (0) 7161 50 44 30 - Fax +49 (0) 7161 50 44 320 - info@medacta.com

Italy - Medacta Italia Srl

Via G. Stephenson, 94 - 20157 Milano
Phone +39 02 390 181 - Fax +39 02 390 00 704 - mail@medacta.it

Japan - Medacta Japan CO. LTD

Chichibuya Bldgs. 2F 3-7-4 Kojimachi, Chiyoda-ku, Tokyo 102-0083
Phone +81 3 6272 8797 - Fax +81 3 6272 8798 - info@medacta.co.jp

Spain - Medacta España SLU

Avda de las Jacarandas - 2 - Edificio CREA Oficina 631- 46100 - Burjassot
Phone +34 (0) 963 484 688 - Fax +34 (0) 963 484 688 - info@medacta.es

UK - Medacta UK Limited

16 Greenfields Business Park - Wheatfield Way - Hinckley - Leicestershire - LE10 1BB
Phone +44 (0) 1455 613026 - Fax +44 (0) 1455 611446 - info@medacta.co.uk

USA - Medacta USA, Inc.

1556 West Carroll Avenue - Chicago - IL 60607
Phone +1 312 878 2381 - Fax +1 312 546 6881 - info@medacta.us.com

Distributors

Argentina	Austria	Belarus	Brazil	Bulgaria	Colombia	Greece
Indonesia	Ireland	Israel	Kuwait	Luxemburg	Malaysia	Mexico
New Zealand	Norway	Slovenia	South Africa	Vietnam		

At the M.O.R.E. Institute the surgeon is never alone when discovering new technologies

Over the last 10 years, the AMIS Education Program has enabled a successful diffusion of the AMIS approach to total hip arthroplasty the world over.